

Use of CT to Diagnose Subcutaneous Emphysema (SE)

Student Researcher: Emily Paciga

Faculty Advisor: Dr. Halesey, Ed.D, R.T(R)(QM)

Introduction

- Within the Medical Imaging community, computed tomography (CT) is an advanced modality that uses ionizing radiation to acquire images. Images are acquired in an axial acquisition and then reconstructed into sagittal and coronal planes.

- CT is the modality of choice when internal injuries are suspected. When diagnosing subcutaneous emphysema, CT is preferred over other imaging modalities.

Etiology

- Subcutaneous emphysema is the infiltration of air underneath the dermal layers of skin. SE may result from traumatic, surgical, infectious or spontaneous etiologies. Common areas of occurrences include but are not limited too, thoracic cavity, sinus cavity, facial bones, and bowel perforations.

- The incidence of an individual developing SE is 0.43%-2.34% (Kukuruza & Aboeed, 2021, p. 1). Males are more likely to suffer from SE.

Pathophysiology

- Injury of the parietal pleura that then allows for air into the pleural and subcutaneous tissues.

- Air from the mediastinum spreading into the cervical viscera and other connected tissue planes.

- Necrotizing infections causing generation of gas.

- Alveolus leaking air into the end-vascular sheath and lung hilum into the endothoracic fascia.

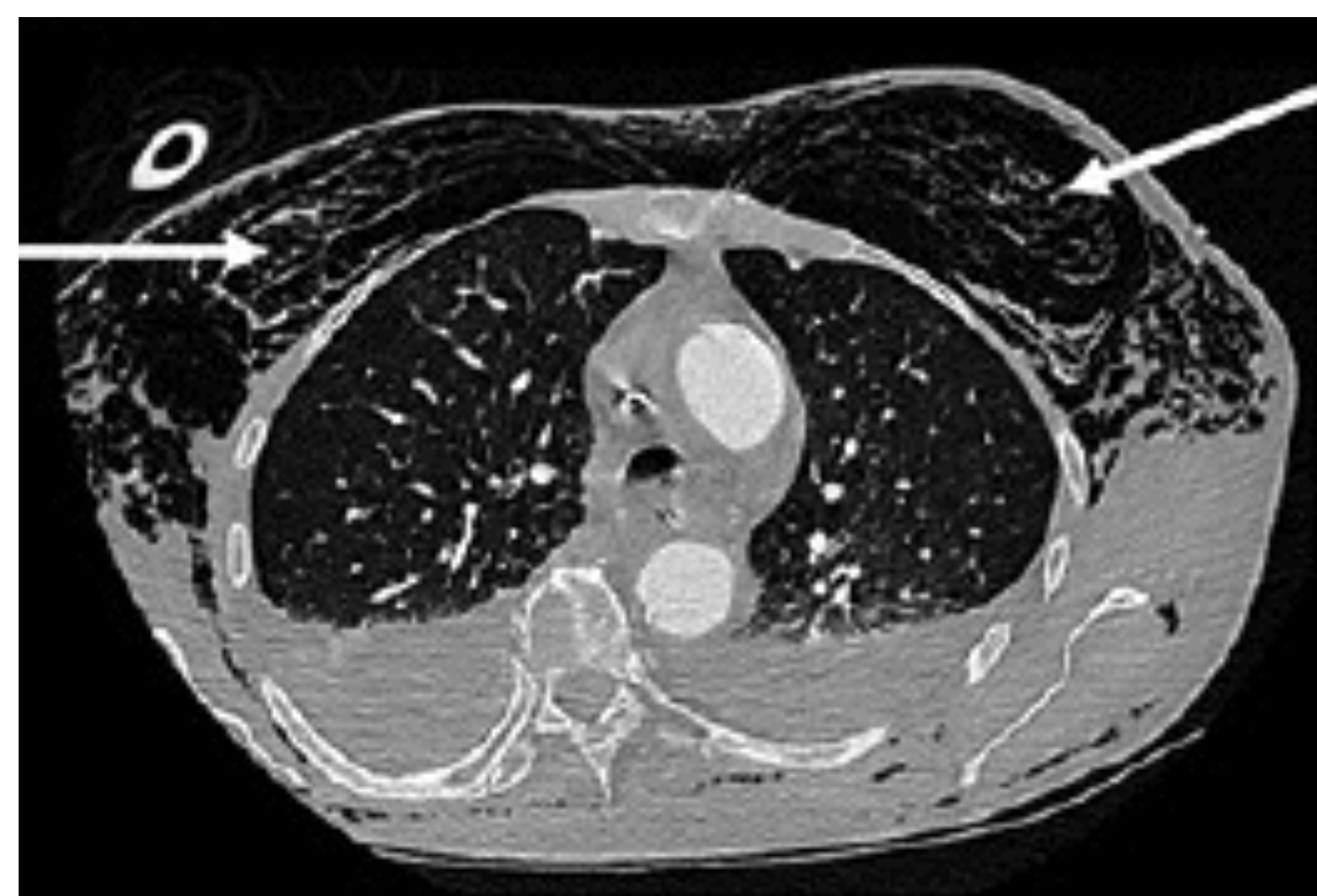


Figure 1 Coronal chest CT demonstrating subcutaneous emphysema in thorax. (Diop, Giabicani, & Legriel, 2021, p. 107)

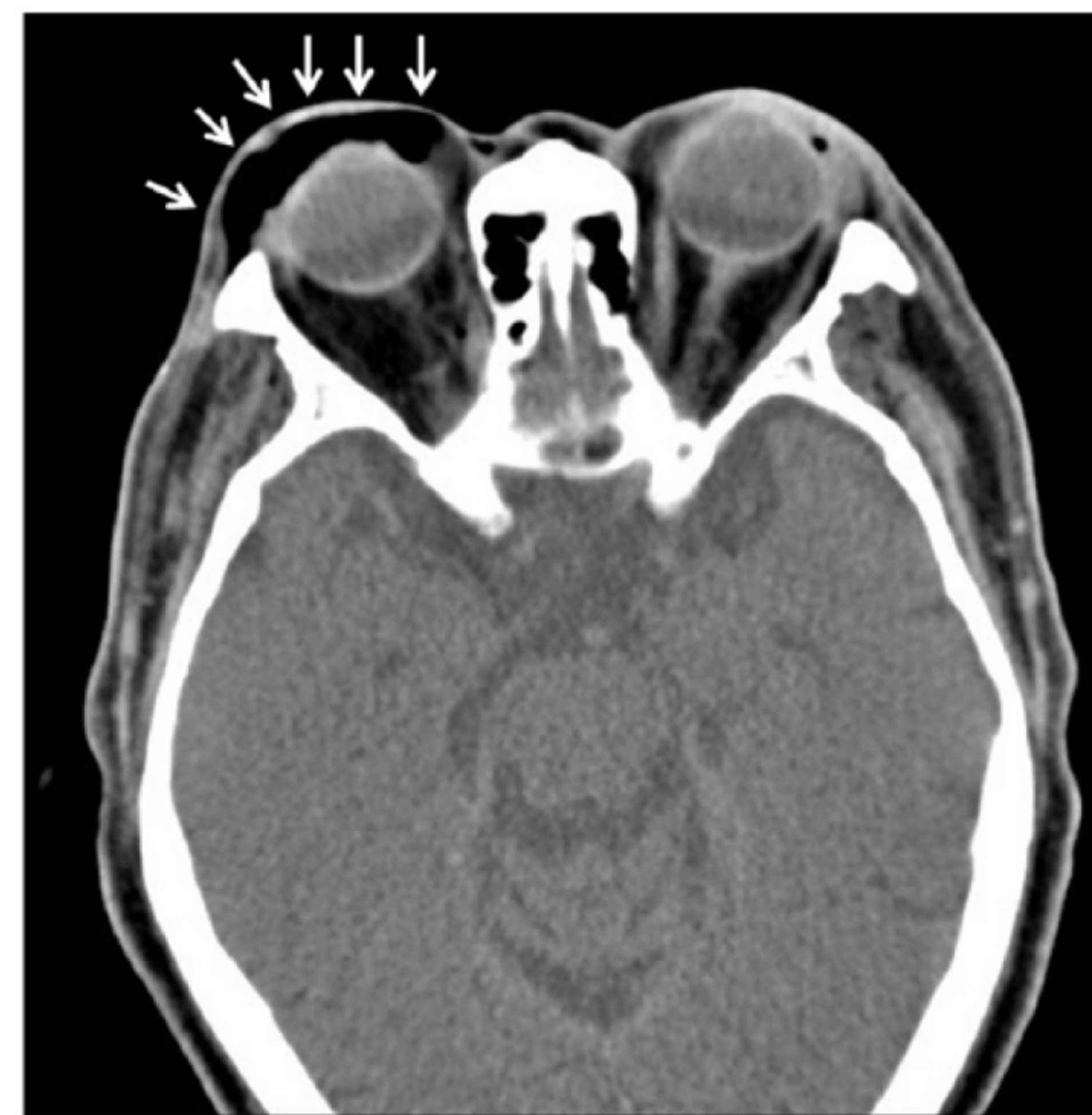

Figure 2 Coronal slice of a CT maxillary face in a soft tissue window width. Demonstrating subcutaneous emphysema surrounding right orbital cavity, periorbital cavity and infra temporal fossa. (Chan, Lio, Yu, Peng, & Chan, 2020, p. 177)

Prognosis

- SE is non-fatal and self-limited and considered benign. However if extensive, SE may be life-threatening and can cause tracheal compression and tissue necrosis. Without intervention, respiratory and cardiovascular impair may occur.

Evaluation

- CT is the modality of choice in diagnosing subcutaneous emphysema. CT will demonstrate dark pockets within the subcutaneous layer of the dermis, indicative of air. Upon palpation, the affected area a crackling sound and sensation known as crepitus (grinding, crunching or popping sound). Furthermore, using a stethoscope emits high-frequency acoustic sounds.

Treatment & Management

- The underlying cause of SE should be first analyzed in treatment. In mild cases, observation is applicable. Resolution of SE most often occurs in less than 10 days if underlying diagnose is controlled (Kukuruza & Aboeed, 2021, p. 2).

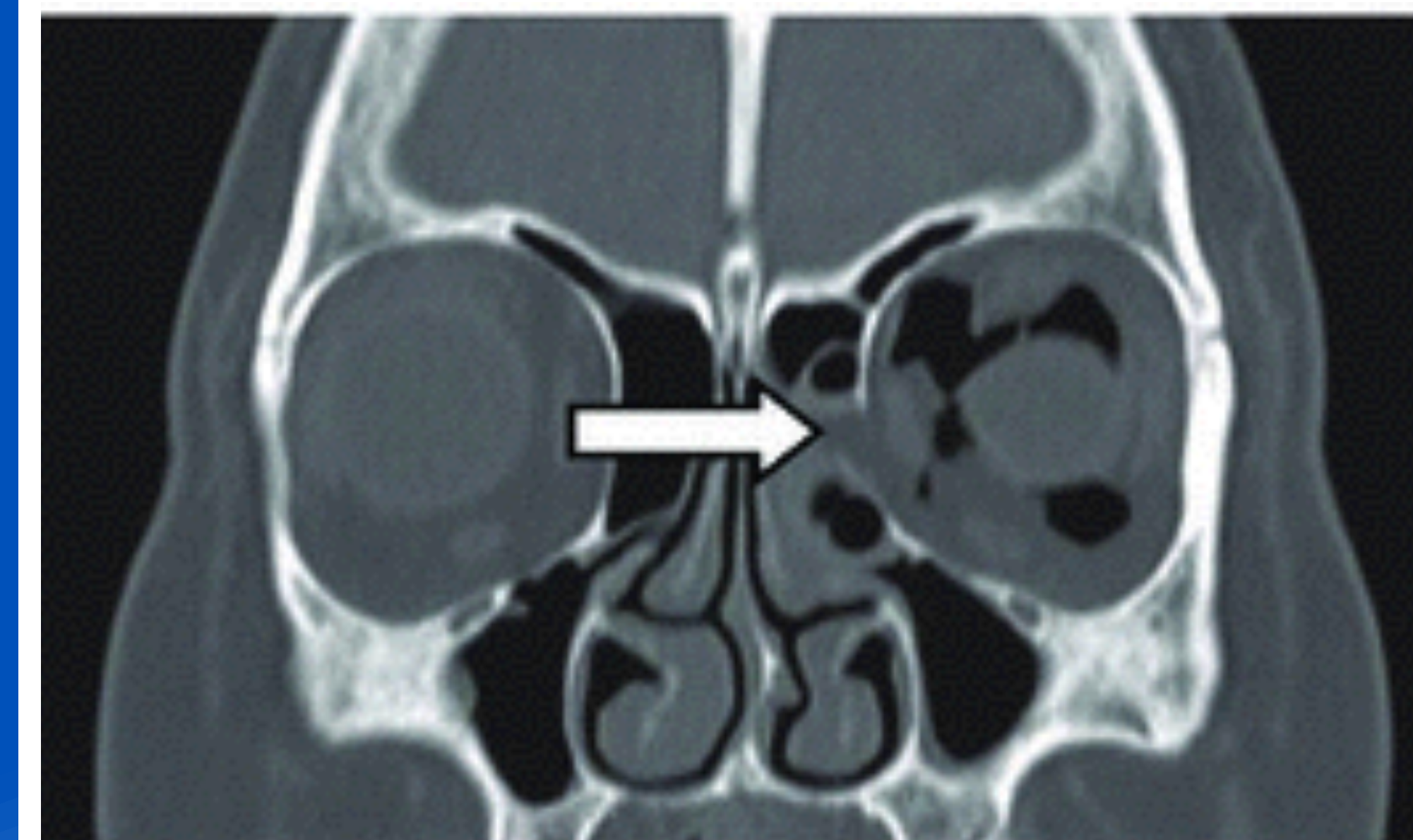

Figure 3 Sagittal CT in soft tissue window width. Demonstrating blow out fracture of the left orbital floor with orbital fat herniation. Periorbital and orbital emphysema revealed. (Ariyoshi et al., 2019, p. 2)

Orbital SE

- Sneezing is a daily involuntary occurrence. Forceful nose-blowing can cause spontaneous SE. When individuals blow their noses, air transfer from the paranasal sinuses into the orbit along a pressure gradient causing a one-way valve forcing air into the orbit (Ariyoshi et al., 2019, p. 2). A CT of the sinuses can measure intranasal pressure during coughing, sneezing, and nose-blowing using fluid dynamic modeling. Depending on the extent and location of SE, temporary or permanent vision loss may occur because of compression of the optic nerve.

Traumatic SE

- Common traumatic areas that cause SE includes trauma to the chest, airway, sinuses, facial bones, intestinal perforation. Air prefers to collect in subcutaneous tissue where tension is minimal until the pressure rises to the point where it migrates along the fascial and anatomical planes (Jadav & Meshram, 2022, p. 2106). Upon palpation, crepitus may be present over the patient's face, chest, abdomen, and limbs. Air tends to migrate upwards from the source of origin. SE is most common on the neck, face and chest.

Surgical SE

- SE may be a iatrogenic (caused by medical treatment) consequence from surgery. For example the presence fo SE after a colonoscopy is common due to the diffusion of insufficient carbon dioxide gas thought the subcutaneous tissue (Diop et al., 2021, p. 107). Aiding in diagnosis, CT is used to determine diagnosis and differentiate SE. alveoli rupture and barotrauma.

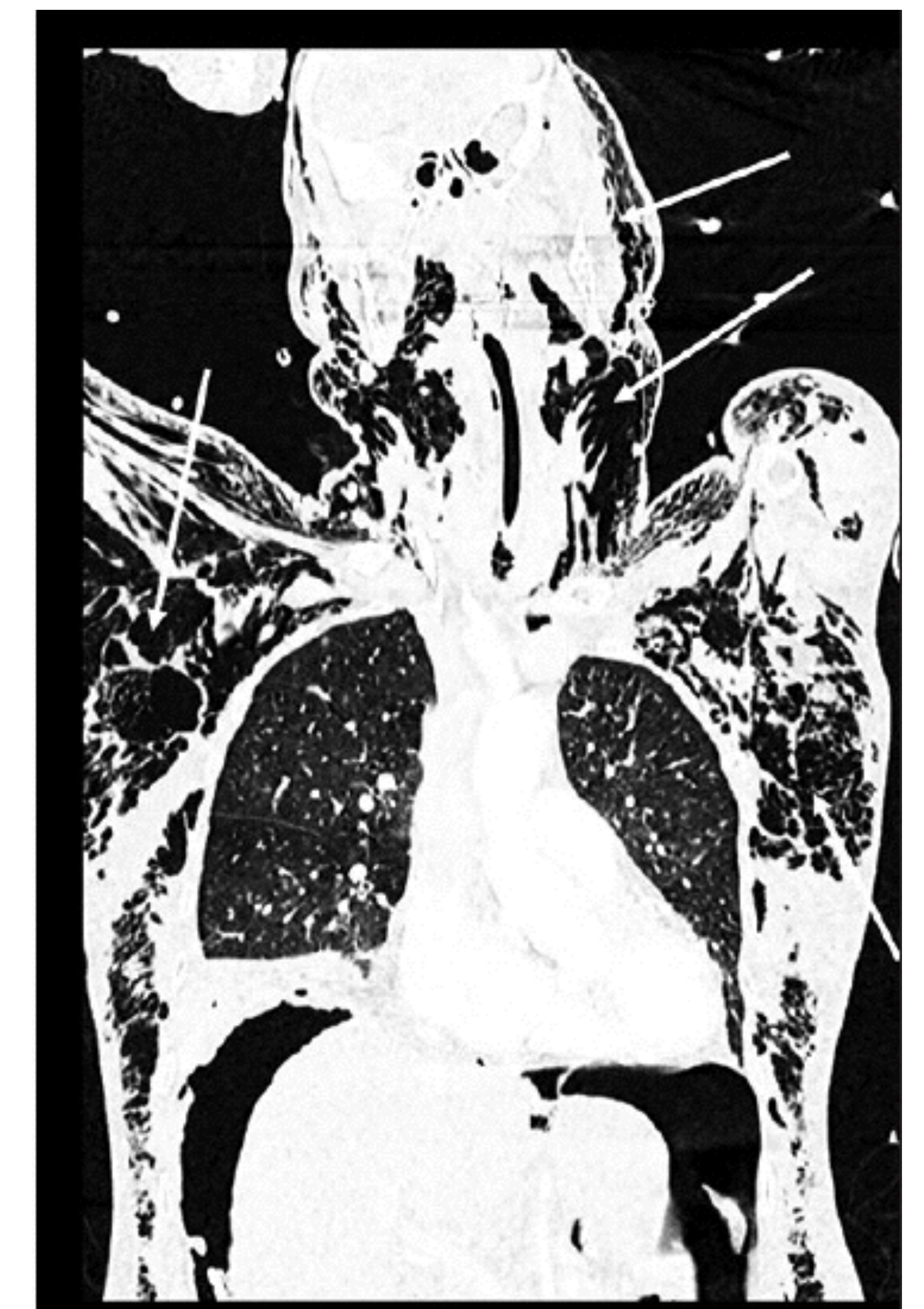

Figure 4 Reconstructed sagittal CT in bone window width. Demonstrating subcutaneous emphysema throughout thorax, neck and skull. (Diop et al., 2021, p. 107)

Conclusion

- Subcutaneous emphysema is a symptom that subsequently follows a more serious condition. SE resolves on its own and is considered benign. Air within the tissues reabsorbs over time.

- Mild SE only requires surveillance of symptoms. For more extensive SE medical involvement may be necessary.

- CT is the imaging modally used to diagnose subcutaneous emphysema because of its ability to detect air within the subcutaneous tissue. CT is also able to demonstrate SE in multiple reconstructed planes and 3D images. Subcutaneous emphysema can be caused from involuntary actions like nose-blowing, traumatic accidents, or as a complication from surgery. SE is not life threatening and a curable symptom.